

Tuberculosis presenting as proliferative glomerulonephritis with monoclonal immunoglobulin deposits

Tuberculosis que se presenta como glomerulonefritis proliferativa con depósitos de inmunoglobulina monoclonal

Özant Helvacı¹, Yasemin Erten², İpek Işık Gönül², Ahmet Özet³, Rauf Haznedar⁴

ABSTRACT

Proliferative glomerulonephritis with monoclonal immunoglobulin deposits is defined as membranoproliferative glomerulonephritis like injury with monotypic Ig deposits restricted to a single light chain isotype.

Here we present a patient who presented with hypocomplementemia and nephrotic syndrome, who was initially diagnosed with proliferative glomerulonephritis with monoclonal immunoglobulin deposits. He developed disseminated tuberculosis after a brief course of immunosuppression. Successful treatment of tuberculosis resulted in the complete remission of glomerular disease and the disappearance of monoclonal protein. Hence, we believe he had Tuberculosis-related proliferative glomerulonephritis with monoclonal immunoglobulin deposits.

Treatment strategies have not been structured due to the rarity of the condition and lack of randomized trials. However, expert opinion suggests clone-based therapy. Proliferative glomerulonephritis with monoclonal immunoglobulin deposits with a benign course without clone-based therapy has been reported. Patients seldom respond to classic immunosuppressants. Even some cases experience slowly progressive disease under angiotensin converting enzyme inhibition alone. There are also cases secondary to viral infections.

Our case and the particular “benign” cases lead us to an intriguing

proposition that proliferative glomerulonephritis with monoclonal immunoglobulin deposits might not be a single disease. A subset of patients may be experiencing infection-related or post-infectious glomerulonephritis presenting as proliferative glomerulonephritis with monoclonal immunoglobulin deposits.

KEYWORDS: proliferative glomerulonephritis with monoclonal immunoglobulin deposits; membranoproliferative glomerulonephritis; monoclonal gammopathy of renal significance; monoclonal gammopathy of undetermined significance; tuberculosis

RESUMEN

La lesión similar a la glomerulonefritis membranoproliferativa con depósitos de Ig monotípicos restringidos a un isotipo de cadena ligera única se conoce actualmente como glomerulonefritis proliferativa con depósitos de inmunoglobulina monoclonal.

A continuación presentamos a un paciente que presentó hipocomplementemia y síndrome nefrótico, al que inicialmente se le diagnosticó glomerulonefritis proliferativa con depósitos de inmunoglobulina monoclonal. Desarrolló tuberculosis diseminada después de un breve curso de inmunosupresión. El tratamiento exitoso de la tuberculosis dio como resultado la remisión completa de la enfermedad glomerular y la

1) Department of Nephrology, Yenimahalle Research and Training Hospital, Yıldırım Beyazıt University, Ankara, Turquía

2) Department of Nephrology, Gazi University, Nephrology, Ankara, Turquía

3) Department of Oncology, Gazi University, Ankara, Turquía

4) Department of Hematology, Gazi University, Ankara, Turquía

Correspondencia:
Dr. Özant Helvacı
ORCID: 0000-0002-1382-2439
drozant@hotmail.com

Conflict of interest:
No conflict of interest.

Recibido: 19-10-2020
Aceptación: 21-11-2020

desaparición de la proteína monoclonal. Por lo tanto, creemos que tenía glomerulonefritis proliferativa con depósitos de inmunoglobulina monoclonal relacionada con tuberculosis diseminada.

Las estrategias de tratamiento no se han estructurado debido a la rareza de la afección y la falta de ensayos aleatorios. Sin embargo, la opinión de los expertos sugiere una terapia basada en clones. Se ha informado de glomerulonefritis proliferativa con depósitos de inmunoglobulina monoclonal con un curso benigno sin terapia basada en clones. Los pacientes rara vez responden a los inmunosupresores clásicos. Incluso algunos casos experimentan una enfermedad de progresión lenta solo con la inhibición de la enzima convertidora de angiotensina. También hay casos secundarios a infecciones virales.

Nuestro caso y los casos “benignos” particulares nos llevan a la propuesta intrigante de que la glomerulonefritis proliferativa con depósitos de inmunoglobulina monoclonal podría no ser una sola enfermedad. Un subgrupo de pacientes puede estar experimentando glomerulonefritis postinfecciosa o relacionada con una infección que se presenta como glomerulonefritis proliferativa con depósitos de inmunoglobulina monoclonal.

PALABRAS CLAVES: glomerulonefritis proliferativa con depósitos de inmunoglobulina monoclonal; glomerulonefritis membranoproliferativa; gammopatía monoclonal de importancia renal; gammopatía monoclonal de significado indeterminado; tuberculosis

INTRODUCTION

Membranoproliferative glomerulonephritis (MPGN) type 1 or immune complex-mediated MPGN might be idiopathic or secondary to infections, autoimmune disorders, monoclonal gammopathy, and cryoglobulinemia.⁽¹⁾ Monoclonal gammopathy (M protein) generally arises from multiple myeloma and rarely from Waldenström's macroglobulinemia, B-cell chronic lymphocytic lymphoma/leukemia, other clonal neoplasia and very infrequently and transiently from chronic infections.⁽²⁾

The International Monoclonal Gammopathy & Kidney Workgroup proposed the term monoclonal gammopathy of renal significance (MGRS) for all

cases of M protein-related kidney disease in 2012.⁽³⁾ MPGN like injury with monotypic Ig deposits restricted to a single light chain isotype is currently known as PGNMID, which is characterized by MPGN (mostly) or mesangio-proliferative type of renal lesion plus monoclonal immunoglobulin deposition.⁽⁴⁾

Here we present a patient who was initially diagnosed with PGNMID. He developed disseminated tuberculosis (Tbc) after a brief course of immunosuppression. Successful treatment of tuberculosis resulted in the complete remission of glomerular disease and the disappearance of monoclonal protein. Hence, we believe he had Tbc-related PGNMID.

CASE REPORT

A 53-year-old man presented with anorexia, nausea, and vomiting. His past medical history was significant for anemia of unknown cause for two years and edema with swelling of his hands for the last nine months. Baseline creatinine was 0.6 mg/dL.

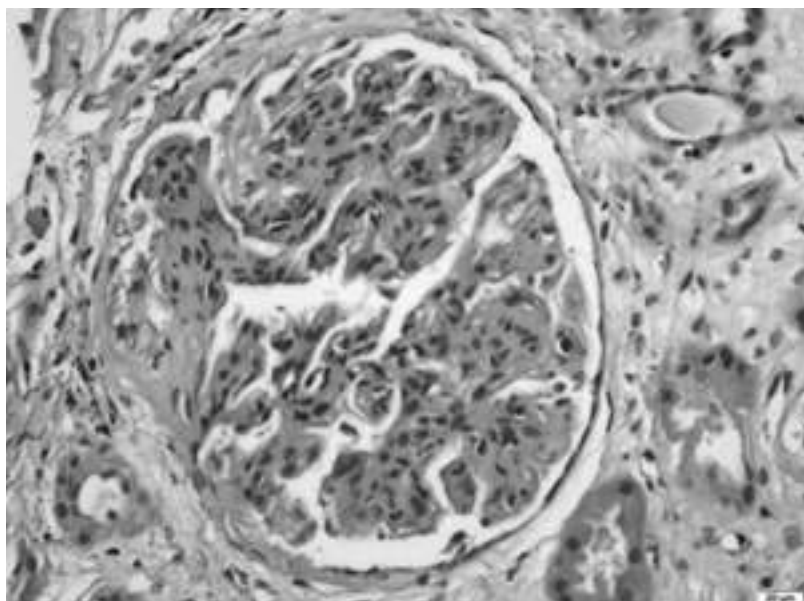
He appeared pale on examination. There was marked acral painful puffiness and lower extremity edema. His blood pressure was 150/100 mmHg. Other physical findings were unremarkable. The serum creatinine was 2.7 mg/dL. Urinalysis showed red blood cells: 23/high power field (HPF), eight granular casts/HPF, nine white blood cells/HPF.

Anemia, hypocomplementemia, elevated sedimentation rate, and nephrotic range proteinuria were notable at initial laboratory tests (**Table 1**). The chest X-ray was normal. Paraphenylenediamine (PPD) was negative. Quantiferon was not obtained.

Kidneys were normal-sized. The renal biopsy obtained 34 glomeruli with homogeneous morphology. All the glomeruli showed lobular accentuation with global mesangial and endocapillary hypercellularity (**Figure 1**). Glomerular capillary walls were thickened in the form of double contours in focal and segmental areas with rare subendothelial and intracapillary hyaline thrombi. Two glomeruli showed cellular crescent formation. Immunofluorescence revealed coarse granular staining along the glomerular capillary walls with IgG, κ , C3 in a diffuse but segmental fashion. Electron microscopy and IgG subtype staining were not available. Renal interstitium was mildly edematous and minimally inflamed with mononuclear inflammatory cell infiltrate.

Table 1. Patient's initial laboratory data

Parameter	Patient's value	Reference
Creatinine (mg/dL)	2.7	0.6-1.1
BUN (mg/dL)	46	10-20
Albumin (gr/dL)	2.3	3.5-5
24-hour urine protein (gr/day)	3.7	<0.3
Hemoglobin (g/dL)	9.8	13.5-17.5
White blood count (/ml)	8600	4-11.000
Ferritin (ng/mL)	545	15-300
Sedimentation (mm/h)	88	0-20
C3 (mg/dL)	35	88-201
C4 (mg/dL)	10	16-47
Anti-nuclear antibody	Negative	Negative
Anti-dsDNA	Negative	Negative
c-ANCA	Negative	Negative
p-ANCA	Negative	Negative
Rheumatoid factor	Negative	Negative
Anti-citrullinated peptide	Negative	Negative

Figure 1. Hypertrophic glomerulus with endocapillary proliferation and thickening in the glomerular capillary walls, H&E stain X400

The histological pattern in the kidney biopsy was consistent with MPGN. We evaluated the patient for bacterial and viral infections, cryoglobulinemia, and plasma cell dyscrasias. HbsAg, Anti-HCV, Anti-HIV, VDRL, and CMV viral load were all negative. Serum immunofixation revealed a peak in IgG k, band. Bone marrow biopsy revealed 1-3% plasma cell infiltration, which was polytypic with k and l. Cryoglobulins

were negative. The patient had MGRS without an apparent malign B or plasma cell clone, in addition to an MPGN pattern injury. Thus, the patient was considered to have PGNMID and started on mycophenolate mofetil (MMF) and methylprednisolone combination. After a month of therapy, his proteinuria decreased to 1550 mg/day. Creatinine also decreased. Steroids were tapered since the findings suggested partial

remission.

However, in the 4th month of therapy, he was admitted with fever, hemoptysis, and worsening general condition. CRP levels were very high. CMV-PCR was negative. Cultures of blood, sputum, throat, and urine were negative for common bacteria and fungi. Cultures of sputum for acid-fast bacilli were negative (three times). Chest X-ray showed the appearance of miliary nodular involvement of the lungs. CT-scan showed a hilar mass of 5x5 cm in diameter, multiple lymphadenopathies, and disseminated miliary nodules on the lungs. MMF was stopped. PET-CT scan was performed to exclude a possible malignancy. However, a pathological FDG uptake in the lungs, spleen, kidneys, prostate, and thoracic lymph nodes was demonstrated. A prostatic biopsy showed caseating granulomas with abundant Ziehl Neelsen (+) acid-fast bacilli. Bronchoscopic samples were also positive for acid-fast bacilli. According to all these findings, a diagnosis of disseminated (miliary) tuberculosis was made. The patient was started on a four-drug regimen of anti-tuberculosis treatment while steroid was tapered and stopped. Mycobacterium tuberculosis, without any drug resistance, finally showed growth on culture media.

The patient's condition gradually improved. He completed ten months of anti-tuberculosis therapy without any problem. His all clinical, biochemical, radiological findings and signs of the disease resolved. In the third month of anti-Tbc treatment, IgG k peak in the serum disappeared. So, his diagnosis evolved to Tbc related immune complex glomerulonephritis. Following the completion of anti-tuberculosis therapy, hemoglobin level was 13.5 g/L, serum creatinine level 0.7 mg/dL, and proteinuria 270 mg/day. He is completely healthy without any symptoms in his fifth year of follow up.

DISCUSSION

In the present case, serum immunofixation demonstrated a monoclonal IgG k band, the same as the IF pattern in the kidney and led to a diagnosis of PGNMID. Bone marrow biopsy excluded multiple myeloma. The patient was diagnosed in the year 2013; by that time, clone-based therapy was unavailable to us, and rituximab was only available off label after demonstrated failure of steroids plus MMF or a calcineurin inhibitor. So, we opted for the former combination. Under

immunosuppressive therapy, Tbc developed. The interruption of immunosuppressive treatment and effective anti-Tbc treatment resulted in the complete recovery.

We think that our case is quite instructive in terms of showing that tuberculosis can cause MPGN-type injury that shows monotypic IgG accumulation limited to a single light chain isotype in glomeruli, which can be called Tbc-related PGNMID.

There are few cases of MPGN in the setting of tuberculosis, all of which showed resolution with anti-tuberculosis therapy, underlying the importance of cross inflammatory mechanisms. In all these cases, severe, longstanding Tbc was evident, so there was no need to search for an M protein.⁽⁵⁾

Furthermore, the monoclonal peak in the serum disappeared with anti-Tbc treatment. That finding leads us to think that Tbc was the primary disease rather than an immunosuppressive therapy-related complication. The co-existence of Tbc and an M protein is well known; however, causality cannot be established for each case.⁽⁶⁾

Experience in PGNMID relies intensely on case series and reports. Nasr *et al.* first offered the term in 2004.⁽⁷⁾ The same authors reported thirty-seven patients in 2009 and only one of which had a recent history of a viral infection like disease.⁽⁸⁾ Based on several case series, the likelihood of discovering a circulating M protein is around 30-40% for PGNMID.⁽⁸⁻¹²⁾

Interestingly, nearly all patients without apparent hematologic involvement, share a common feature: renal-limited disease. Learning on this knowledge, it would be fair to say the unexplained anemia, and arthropathy should have warned us to look deeper for an underlying cause.

Expert opinion suggests either plasma-cell directed therapies or rituximab for PGNMID.⁽¹⁰⁾ Due to the rarity of PGNMID and lack of randomized trials, treatment strategies have not been structured. Furthermore, the absence of an identifiable clone in most patients creates difficulties in obtaining clone-based therapies.⁽¹³⁾ Response to corticosteroids, MMF, and calcineurin-inhibitor cannot be readily assessed; however, in each case series, some patients have responded well. Even some cases experience slowly progressive disease under angiotensin converting enzyme (ACE) inhibition alone.⁽⁸⁻¹²⁾ Van Kruijsdijk *et al.* recently

reported two cases of PGNMID with a benign course without the need for clone based therapies.

⁽¹⁴⁾ Furthermore, PGNMID has been reported after probable viral infections. Fujita *et al.* reported two cases related to Parvovirus B19 infections.⁽¹⁵⁾

Our case and the particular “benign” cases lead us to an intriguing proposition that PGNMID might not be a single disease. While a subset of patients suffers from MGRS related PGNMID with a satisfactory response to clone-based treatments, another subgroup of patients may be experiencing infection-related or post-infectious glomerulonephritis presenting as PGNMID.

CONCLUSION

Tuberculosis can present as PGNMID. The presence of extra-renal symptoms should warrant Tbc evaluation, especially in the endemic parts of the World. The question of whether PGNMID is a single disease or not needs further studies to be replied.

BIBLIOGRAFÍA

- 1) Fogo AB, Lusco MA, Najafian B, Alpers CE. AJKD Atlas of Renal Pathology: Membranoproliferative Glomerulonephritis. *Am J Kidney Dis.* 2015;66(3):e19-20. doi: 10.1053/j.ajkd.2015.07.007.
- 2) Hogan JJ, Alexander MP, Leung N. Dysproteinemia and the Kidney: Core Curriculum 2019. *Am J Kidney Dis.* 2019;74(6):822-36. doi: 10.1053/j.ajkd.2019.04.029.
- 3) Leung N, Bridoux F, Hutchison CA, Nasr SH, Cockwell P, Ferman J, *et al.*; International Kidney and Monoclonal Gammopathy Research Group. Monoclonal gammopathy of renal significance: when MGUS is no longer undetermined or insignificant. *Blood.* 2012;120(22):4292-5. doi: 10.1182/blood-2012-07-445304.
- 4) Sethi S, Fervenza FC, Rajkumar SV. Spectrum of manifestations of monoclonal gammopathy-associated renal lesions. *Curr Opin Nephrol Hypertens.* 2016;25(2):127-37. doi: 10.1097/MNH.0000000000000201.
- 5) Solak Y, Gaipov A, Anil M, Atalay H, Ozbek O, Turkmen K, *et al.* Glomerulonephritis associated with tuberculosis: a case report and literature review. *Kaohsiung J Med Sci.* 2013;29(6):337-42. doi: 10.1016/j.kjms.2012.10.008.
- 6) Bida JP, Kyle RA, Therneau TM, Melton LJ 3rd, Plevak MF, Larson DR, *et al.* Disease associations with monoclonal gammopathy of undetermined significance: a population-based study of 17,398 patients. *Mayo Clin Proc.* 2009;84(8):685-93. doi: 10.1016/S0025-6196(11)60518-1.
- 7) Nasr SH, Markowitz GS, Stokes MB, Seshan SV, Valderrama E, Appel GB, *et al.* Proliferative glomerulonephritis with monoclonal IgG deposits: a distinct entity mimicking immune-complex glomerulonephritis. *Kidney Int.* 2004;65(1):85-96. doi: 10.1111/j.1523-1755.2004.00365.x.
- 8) Nasr SH, Satoskar A, Markowitz GS, Valeri AM, Appel GB, Stokes MB, *et al.* Proliferative glomerulonephritis with monoclonal IgG deposits. *J Am Soc Nephrol.* 2009;20(9):2055-64. doi: 10.1681/ASN.2009010110.
- 9) Bhutani G, Nasr SH, Said SM, Sethi S, Fervenza FC, Morice WG, *et al.* Hematologic characteristics of proliferative glomerulonephritides with nonorganized monoclonal immunoglobulin deposits. *Mayo Clin Proc.* 2015;90(5):587-96. doi: 10.1016/j.mayocp.2015.01.024.
- 10) Gumber R, Cohen JB, Palmer MB, Kobrin SM, Vogl DT, Wasserstein AG, *et al.* A clone-directed approach may improve diagnosis and treatment of proliferative glomerulonephritis with monoclonal immunoglobulin deposits. *Kidney Int.* 2018;94(1):199-205. doi: 10.1016/j.kint.2018.02.020.
- 11) Sethi S, Rajkumar SV. Monoclonal gammopathy-associated proliferative glomerulonephritis. *Mayo Clin Proc.* 2013;88(11):1284-93. doi: 10.1016/j.mayocp.2013.08.002.
- 12) Xing G, Gillespie R, Bedri B, Quan A, Zhang P, Zhou XJ. Proliferative glomerulonephritis with monoclonal IgG deposits in children and young adults. *Pediatr Nephrol.* 2018;33(9):1531-8. doi: 10.1007/s00467-018-3949-8.
- 13) Bridoux F, Javaugue V, Nasr SH, Leung N. Proliferative glomerulonephritis with monoclonal immunoglobulin deposits: a nephrologist perspective. *Nephrol Dial Transplant.* 2021;36(2):208-15. doi: 10.1093/ndt/gfz176.
- 14) van Kruijsdijk RCM, Abrahams AC, Nguyen TQ, Minnema MC, Jacobs JFM, Limper M. Clone-directed therapy for proliferative glomerulonephritis with monoclonal immunoglobulin depositions: is it always necessary? Two case reports and literature review. *J Nephrol.* 2020;33(3):611-7. doi: 10.1007/s40620-020-00723-2.
- 15) Fujita E, Shimizu A, Kaneko T, Masuda Y, Ishihara C, Mii A, *et al.* Proliferative glomerulonephritis with monoclonal immunoglobulin G3κ deposits in association with parvovirus B19 infection. *Hum Pathol.* 2012;43(12):2326-33. doi: 10.1016/j.humpath.2012.04.004.